

Case Report

Nasal stent: A prosthetic solution to maintain airway patency

Anushri Bajoria¹, Kasim Mohamed¹ ¹Department of Prosthodontics, Sri Ramachandra Dental College and Hospital, Chennai, Tamil Nadu, India.**ABSTRACT**

Nasal stents are prosthetic devices designed to maintain airway patency, especially in cases of nasal stenosis resulting from congenital or acquired defects. Prosthetic nasal stents offer a minimally invasive alternative, assisting to support cartilage-deficient tissues and preserving the shape of the nostrils while promoting proper wound healing. This case report presents a 28-year-old male with unilateral post-surgical alar collapse following cleft lip revision surgery. A custom-made nasal stent was fabricated and successfully inserted to restore airway patency and maintain nasal contour.

Keywords: Cleft lip and palate repair, Nasal stent, Nasal prosthesis, Nasal stenosis,

INTRODUCTION

The human face's most striking element is the nose, a complex structure consisting of an osseocartilaginous framework enveloped by layers of soft tissue. The nostrils, or nares, serve as the entry point for air to the lungs.^[1] Located at the nostrils, the external nasal valve is formed by the lower lateral cartilage, soft-tissue ala, and is bordered by the columella and septum medially. The nose has several important functions which include breathing, filtration, humidification, warming, resonance, and speech. Any blockage in this passage, whether from congestion, allergies, or anatomical variations due to congenital or acquired defects, can impair these functions. One of the complications that can arise is nostril stenosis, which may occur as a result of infection, trauma, burn injuries, iatrogenic causes, or conditions such as cleft lip and palate. Stenosis can lead to symptoms such as mouth breathing, discomfort, and esthetic concerns. Nostril narrowing and flattening can occur when the ala's delicate fibrofatty or fibromuscular tissues sustain injury. In cases of alar collapse, reconstructive or rehabilitative procedures aim to restore both the anatomy and the function of the nostril. Various surgical techniques for correcting nasal stenosis include the use of flaps and grafts, although complications such as restenosis are well documented.^[2,3] Therefore, using a prosthetic nasal stent to support cartilage-deficient nasal tissue assists in maintaining the contour of the nostril during wound healing, preserving airway patency, and improving esthetics.^[4] This case report presents a patient with unilateral

post-surgical alar collapse managed with a customized nasal stent.

CASE REPORT

A 28-year-old male was referred from the plastic surgery department for fabrication of a nasal stent to maintain airway patency after cleft lip–nose revision with open rhinoplasty. He had a history of cleft lip and palate repair when he was 1 years old and now complained of nasal stuffiness and absence of left nostril opening. There was no relevant past medical history. On extraoral examination, a lip scar was present, nasal deformity was evident, and notching of the tip of the nose was seen. On intraoral examination, all teeth were present and no malocclusion was evident. Alveolar bone grafting and nasal floor reconstruction was done using nasal skin. The alveolar mucoperiosteal flap was elevated and the alveolar defect was bridged using medullary calcaneus bone harvested from the right iliac crest. Nasal packing was done and hemostasis was secured. After 2 weeks of the surgery, the patient reported nasal deformity and stricture of the right nostril.

A conformer [Figure 1] was made using modeling wax (Hindustan Modeling Wax No. 2, HDP, India) of length and width, which was slightly greater than the actual dimensions of the existing internal nares. The conformer was replicated with alginate (Plastalgin, Septodont Healthcare India Pvt. Ltd.) [Figure 2] and a negative replica was made [Figure 3]. A wire was luted with wax and placed in the center to obtain airway patency in the final prosthesis. Acrylization was

***Corresponding author:** Kasim Mohamed, Department of Prosthodontics, Sri Ramachandra Dental College and Hospital, Chennai, Tamil Nadu, India. kasimmohamed@sriramachandra.edu.in

Received: 10 September 2024 **Accepted:** 06 January 2025 **EPub Ahead of Print:** 19 February 2025 **Published:** XXXXXX **DOI:** 10.25259/SRJHS_17_2024

This is an open-access article distributed under the terms of the Creative Commons Attribution-Non Commercial-Share Alike 4.0 License, which allows others to remix, transform, and build upon the work non-commercially, as long as the author is credited and the new creations are licensed under the identical terms. ©2024 Published by Scientific Scholar on behalf of Sri Ramachandra Journal of Health Sciences



Figure 1: Wax conformer.



Figure 4: Nasal stent.

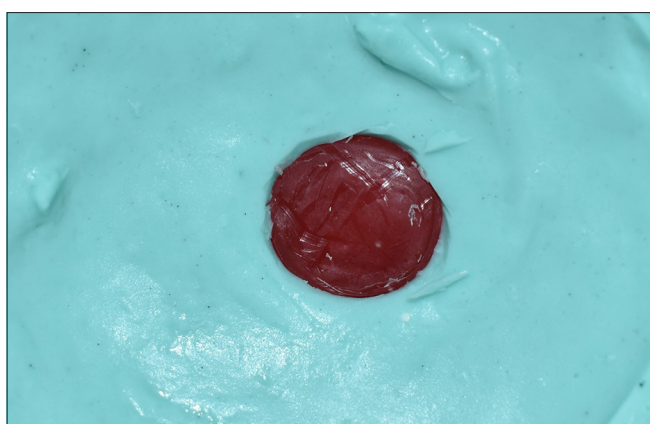


Figure 2: Alginate duplication.




Figure 3: Impression.

done using auto-polymerizing resin (Auto-polymerizing – polymethyl methacrylate [PMMA] resin – DPI-RR cold cure, India). The wire was removed and the hole dimensions were increased. It was trimmed and highly polished [Figure 4] and cleaned with a disinfectant (10% aqueous solution of povidone-iodine - Betadine) before inserting in the nares. The fit was tight and it was self-retentive [Figures 5 and 6].

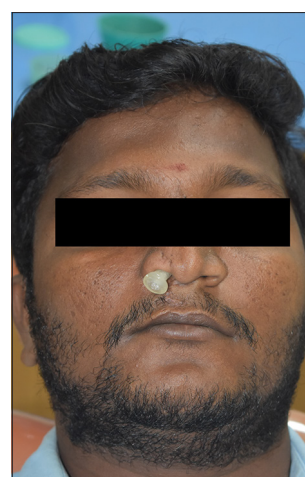

Figure 5: Nasal stent insertion frontal view.

Post-insertion instructions were given. The patient was reviewed after 24 h, then 1 week. The patient was advised to use the stent for 3 months.

DISCUSSION

A variety of surgical techniques are employed for repairing cleft lip and palate, with no established consensus among surgeons regarding the best protocol, timing, or technique for repair. Cleft lip and palate surgeries showed promising results, with nearly 7 in 10 cases (68.8%) yielding positive outcomes. Specifically, lip repairs achieved favorable esthetic scores for both lip and nose in 67.9% of cases. Palatal repairs were slightly more successful, with 70.2% attaining good surgical results. Despite these encouraging figures, it is important to note that almost one-third (29.8%) of cleft palate repairs resulted in oronasal fistula formation.^[5] When treating nasal obstructions, particularly those in the anterior region such as the external valve and vestibule, clinicians aim to balance three key objectives: preserving airway patency, preventing tissue damage, and optimizing

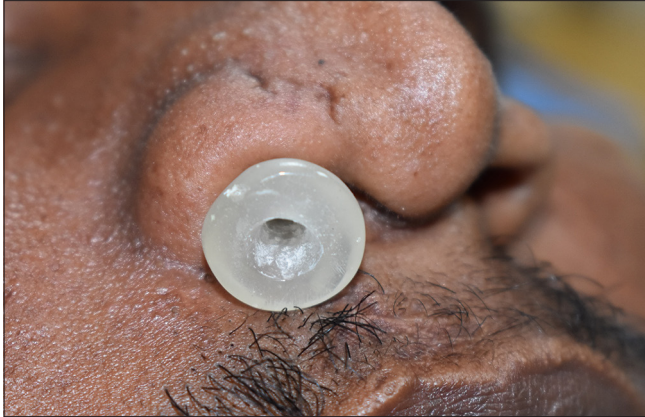

Figure 6: Nasal stent insertion lateral view.

patient comfort throughout recovery. To achieve these goals, custom-fabricated stents, typically made of acrylic or silicone, are often employed. Hard acrylic resin stents are especially favored for their versatility - they can be meticulously sculpted, easily adjusted, and refined to a smooth surface, making them well-suited for delicate nasal anatomy.^[6]

In the case report discussed, the customized intranasal stent effectively restored nasal airways and maintained the patency of the passage following rehabilitative nasal surgery. These stents provided support to the nasal tissues and allowed unobstructed airflow through the nasal cavities. The advantages of using such a stent include its non-invasive nature, cost-effectiveness, and ease of fabrication.

A study by Tripathi *et al.*^[7] evaluated the safety and efficacy of an intraoperatively placed silicone intranasal airway device in rhinoplasty and nasal surgery. The study analyzed 302 operations in 300 patients, including both primary and revision septorhinoplasty. It was found that 76% of participants had either full patency or only partial obstruction, compared to 24% who experienced total obstruction. The study concluded that the device is easily endured and secure for maintaining nasal airway patency.

Nasal stents are valuable tools in the management of post-operative nasal conditions, such as septoplasty or nasal fracture repair, by helping to maintain patency, prevent adhesions, and promote healing. However, their use requires careful consideration of potential complications, including discomfort, infection, nasal obstruction, and mucosal irritation. Close monitoring, patient education on proper care, and timely removal are essential to optimize the outcomes and minimize the risks. While nasal stents can significantly aid in recovery, they should be used as part of a comprehensive, individualized treatment plan tailored to the patient's needs, with attention to both short-term benefits and long-term recovery.

CONCLUSION

Employing a customized nasal stent offers a readily acceptable, comfortable, cost-effective, and minimally invasive solution for treating post surgical nasal stenosis, particularly when the obstruction is located in the anterior part of the nasal passage. This type of prosthesis is straightforward to create and helps maintain adequate breathing with satisfactory esthetic outcomes, while also reducing the risk of post-healing scarring.

Ethical approval

Institutional Review Board approval is not required.

Declaration of patient consent

The authors certify that they have obtained all appropriate patient consent.

Financial support and sponsorship

Nil.

Conflicts of interest

There are no conflicts of interest.

Use of artificial intelligence (AI)-assisted technology for manuscript preparation

The authors confirm that there was no use of artificial intelligence (AI)-assisted technology for assisting in the writing or editing of the manuscript and no images were manipulated using AI.

REFERENCES

1. Egan KK, Kim DW. A novel intranasal stent for functional rhinoplasty and nostril stenosis. *Laryngoscope* 2005;115:903-9.
2. Hafezi F, Pegahmehar M, Nouhi A. Single-stage aesthetic restoration of severely disfigured nose in burn injuries. *Burns* 2002;28:512-8.
3. Meyer R, Jovanovic B, Derder S. All about nasal valve collapse. *Aesthetic Plast Surg* 1996;20:141-51.
4. Chen PH, Seidenfaden JC, Kase MT, Sooudi I. Fabricating a partial nasal prosthesis with a custom nasal dilator design. *J Prosthet Dent* 2021;126:447-51.
5. Abdurrazaq T, Micheal A, Lanre A, Olugbenga O, Akin L. Surgical outcome and complications following cleft lip and palate repair in a teaching hospital in Nigeria. *Afr J Paediatr Surg* 2013;10:345.
6. Chander KS, Komala J, Reddy R, Umair M, Rajender K, Venkatesh K. Prosthetic rehabilitation of bilateral external nasal valve area after nasal reconstruction for a congenitally missing nose: A clinical report. *J Int Oral Health* 2015;7:80-2.
7. Tripathi PB, Majd P, Ngo T, Gu JT, Sharma GK, Badger C, *et al.* Evaluation of safety and efficacy for an intranasal airway device in nasal surgery. *JAMA Facial Plast Surg* 2019;21:38-43.

How to cite this article: Bajoria A, Mohamed K. Nasal stent: A prosthetic solution to maintain airway patency. *Sri Ramachandra J Health Sci.* doi: 10.25259/SRJHS_17_2024